

Treatment of Inflammatory Facial Acne Vulgaris With Combination 595-nm Pulsed-Dye Laser With Dynamic-Cooling-Device and 1,450-nm Diode Laser

Adrienne S. Glaich, MD,¹ Paul M. Friedman, MD,^{1,2*} Ming H. Jih, MD, PhD,¹ and Leonard H. Goldberg, MD, FRCP^{1,3}

¹*DermSurgery Associates, Houston, Texas 77030*

²*University of Texas School of Medicine, Houston, Texas 77030*

³*Department of Medicine (Dermatology), University of Texas, MD Anderson Cancer Center, Houston, Texas 77030*

Background and Objectives: The 585-nm pulsed-dye laser and the 1,450-nm diode laser have been found effective for the treatment of mild-to-moderate inflammatory facial acne. This study was designed to evaluate the efficacy and safety of the combined treatment with the 595-nm pulsed-dye laser and the 1,450-nm diode laser for inflammatory facial acne.

Study Design/Materials and Methods: Fifteen patients with inflammatory facial acne were treated with a combination of the 595-nm pulsed-dye laser and the 1,450-nm diode laser. Patients' subjective response to treatment was evaluated regarding improvement in acne, acne scarring, oiliness, and redness of the skin.

Results: All patients had reductions in acne lesion counts. Mean lesion counts decreased 52% ($P < 0.01$), 63% ($P < 0.01$), and 84% ($P < 0.01$) after one, two, and three treatments, respectively. Patients described moderate-to-marked improvement in acne, acne scarring, and post-inflammatory erythema. Adverse effects were limited to mild, transient erythema.

Conclusions: The combination of the 595-nm pulsed-dye laser and the 1,450-nm diode laser is safe and effective for the treatment of inflammatory facial acne, acne scarring, and post-inflammatory erythema. *Lasers Surg. Med.* 38: 177–180, 2006. © 2005 Wiley-Liss, Inc.

Key words: acne vulgaris; 1,450-nm diode laser; laser therapy; pulsed-dye laser

INTRODUCTION

Even though acne is usually a self-limiting and non-life threatening disease, individuals with facial acne experience physical and mental anguish driving them to seek effective treatment. If not treated adequately, acne can result in permanent scarring of the affected area. Between the ages of 15–44, 29% of women and 34% of men have active acne lesions in the United States [1].

The pathogenesis of acne can be attributed to four key factors: (1) excess sebum production, (2) follicular epithelial hyperproliferation and resultant follicular plugging, (3) the presence of *Propionibacterium acnes* and the production of prefatty acids, and (4) follicular and perifollicular inflammation [2]. Multiple treatment options have been used to

target one or more of these pathogenic elements. These include topical preparations, oral antibiotics, and oral isotretinoin, which may be needed for long periods in a combination of complicated regimens. More recently, various forms of phototherapy including blue light, red light, violet light, ultraviolet light, the long pulse diode laser, and the pulsed-dye laser have been utilized to treat acne [3–8].

The 1,450-nm diode laser in conjunction with a cryogen cooling system has been successful in treating inflammatory acne on the face and back [6–8]. This laser heats the dermis, while the cryogen spray cooling protects the epidermis [7]. The pulsed-dye laser has been effective in the management of inflammatory acne. Pulsed-dye lasers emit visible light that is absorbed primarily by oxyhemoglobin. The pulsed-dye laser appears to kill *P. acnes* containing porphyrins, and also reduces vascularity thereby altering the inflammatory response of active acne as well as decreasing post-inflammatory erythema [3,9,10].

We tested the efficacy and safety of combining the 595-nm pulsed-dye laser with the dynamic-cooling device in conjunction with the 1,450-nm diode laser for the treatment of inflammatory acne vulgaris.

MATERIALS AND METHODS

Fifteen patients (4 males and 11 females) with active inflammatory acne vulgaris were evaluated in this study which was conducted in a private practice setting after obtaining informed consent. Their Fitzpatrick skin types ranged from type II to type IV and their ages ranged from 15–29 years (mean 22 ± 4). Patients with at least five inflammatory acne lesions were enrolled in the study. Exclusion criteria included pregnancy, treatment with oral isotretinoin within the past 6 months, and treatment with

Presented at the 25th Annual Meeting of the American Society for Laser Medicine and Surgery, Lake Buena Vista, Florida, April 3, 2005.

*Correspondence to: Paul M. Friedman, MD, DermSurgery Laser Center, 7515 Main Street, Suite 210, Houston, TX 77030. E-mail: pmfriedman@dermsurgery.org

Accepted 26 May 2005

Published online 22 September 2005 in Wiley InterScience (www.interscience.wiley.com).

DOI 10.1002/lsm.20209

dermal fillers within the past 3 months. Patients were allowed to continue concurrent acne medications which included topical agents (benzoyl peroxides, antibiotics, and retinoids) and oral antibiotics (doxycycline and minocycline). Seven patients had previously completed at least one course of oral isotretinoin.

A topical preparation containing 10% benzocaine, 6% lidocaine, and 4% tetracaine (Triple Anesthetic®; New England Compounding Center, Framingham, MA) was applied under occlusion 1 hour before treatment. Affected areas of the face were first treated with non-overlapping single pulses of the 595-nm pulsed-dye laser (Vbeam; Candela Corporation, Wayland, MA). An integrated dynamic-cooling device set at 30/30 milliseconds was used to cool the epidermis. Treatment fluences ranged from 6.5–7.5 J/cm², using a 10 mm spot size and a 6–10 milliseconds pulse width. Following treatment with the pulsed-dye laser, the entire face was treated with single non-overlapping pulses of the 1,450-nm diode laser (Smoothbeam; Candela Corporation, Wayland, MA). The fluences delivered ranged from 10 to 14 J/cm² using a 6-mm spot size and the integrated dynamic-cooling device set at 30–40 milliseconds. Immediately after treatment a moisturizing cream and sunscreen were applied to the treated skin. The treatments were performed, each separated by a 4–6 week period.

Prior to treatment at each clinic visit, digital photographs were taken. Inflammatory lesions, including papules, pustules, and cysts were counted clinically, and complications were assessed. After at least three treatments, the patients' subjective response to treatment was evaluated regarding improvement of acne lesions, acne scarring, oiliness, and redness in addition to their overall satisfaction with the treatment. Improvements in lesion counts from baseline were compared using the paired Student's *t*-test.

RESULTS

Acne lesion counts were evaluated 4–6 weeks after each treatment. All patients treated demonstrated a marked reduction in their acne lesion counts. The mean acne lesion count decreased from 19 ± 18 to 9 ± 9 ($P < 0.01$) after the first treatment, and 7 ± 5 ($P < 0.01$) and 3 ± 3 ($P < 0.01$) after the second and third treatments, respectively (Fig. 1). This corresponded to a percent reduction of mean

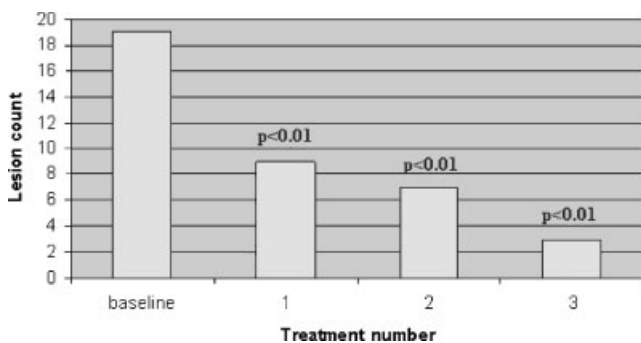


Fig. 1. Mean inflammatory acne lesion count after one, two, and three treatments with the combination of the 595-nm pulsed-dye laser and the 1,450-nm diode laser.

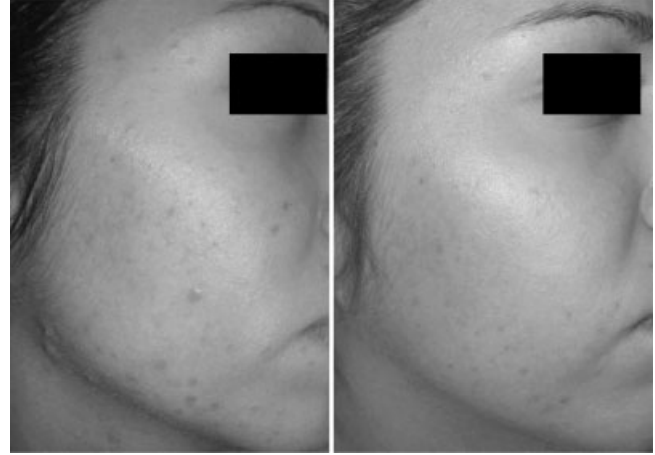


Fig. 2. **Left:** Right cheek pre-treatment with multiple inflammatory papules. **Right:** Thirteen weeks after three treatments with the combination of the 595-nm pulsed-dye laser and the 1,450-nm diode laser, a 94% decrease in lesion count was observed from baseline, as well as marked improvement in post-inflammatory erythema.

acne lesion count of 52% after one treatment, 63% after two treatments, and 84% after three treatments. There was no difference in reduction of acne lesions between males and females ($P > 0.05$) as both showed significant improvements ($P < 0.02$). Figures 2 and 3 are photographs of two patients who received treatment. Of the 15 patients treated, 2 patients returned to college in a different city and did not return for follow-up visits, and 2 patients were in a serious automobile accident and discontinued the treatment.

Patients were allowed to continue the use of topical and oral medications during their treatment. Topical therapies used included benzoyl peroxide (11 patients), clindamycin

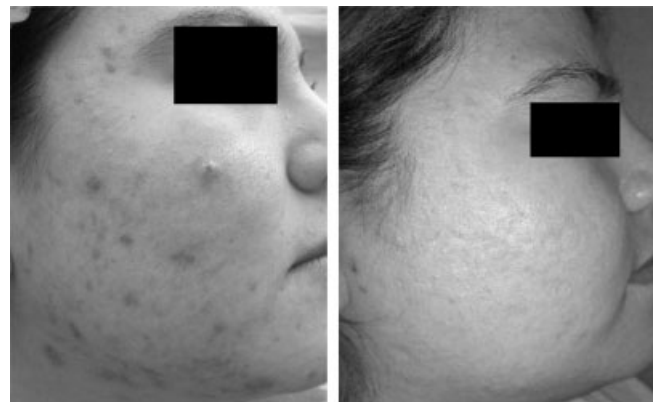


Fig. 3. **Left:** Multiple inflammatory papules on the right cheek pre-treatment. **Right:** Four weeks after three treatments with the combination of the 595-nm pulsed-dye laser and the 1,450-nm diode laser. Marked improvements in post-inflammatory erythema and acne scarring are noted.

phosphate (9 patients), retinoids (6 patients), glycolic acid pads (3 patients), and azelaic acid (1 patient). There were four patients on oral antibiotics including doxycycline (two patients) and minocycline (two patients). All patients on topical therapies as well as those with a combination of topical therapies and oral antibiotics showed improvement. The one patient not using any concomitant therapy had a lesion count that decreased from 18 to 1 after 3 treatments.

Eleven subjects completed a questionnaire regarding their improvement in acne lesions, acne scarring, oiliness, and redness. The results are displayed in Figures 4 and 5. All patients were satisfied with their treatment. Forty-five percent reported being “satisfied” and 55% reported being “highly satisfied” with treatment. One hundred percent of patients said they would recommend this treatment to others.

Pain was well tolerated by all patients after the application of Triple Anesthetic[®] cream 1 hour before treatment. A higher level of pain was experienced during treatment with the 1,450-nm diode laser. More discomfort was expressed when treating the nose, perioral area, and active inflammatory lesions. Adverse effects were limited to mild, transient erythema, and edema at the treatment sites that lasted 24–48 hours. No other adverse effects such as hyperpigmentation, purpura, or scarring were observed.

DISCUSSION

Our study demonstrates that the combination of the pulsed-dye laser and the 1,450-nm diode laser is a safe and effective modality for treatment of inflammatory facial acne and post-inflammatory erythema. Patients described a reduction in oiliness of their skin, possibly eliminating an important medium for bacterial growth [6,7].

The 1,450-nm diode laser in conjunction with a cryogen cooling system has been used to treat inflammatory acne on the face and back [6–8]. Paithankar et al. [7] studied patients with inflammatory acne on the back. One area of the back was treated with the 1,450-nm diode laser while another area of the back was treated only with the cryogen-cooling device, the control. This study revealed a statistically and clinically significant reduction in acne lesions

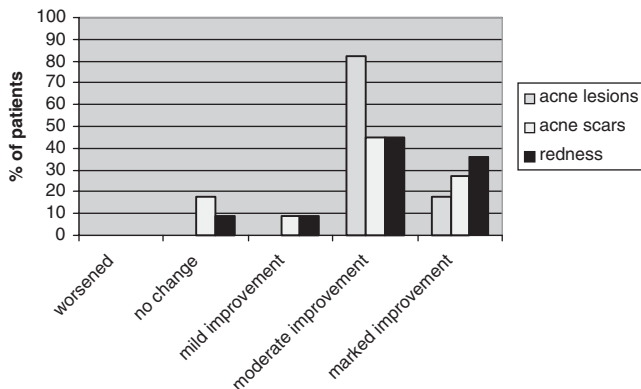


Fig. 4. Patients' subjective responses to improvements in acne lesions, acne scars, and redness after three treatments.

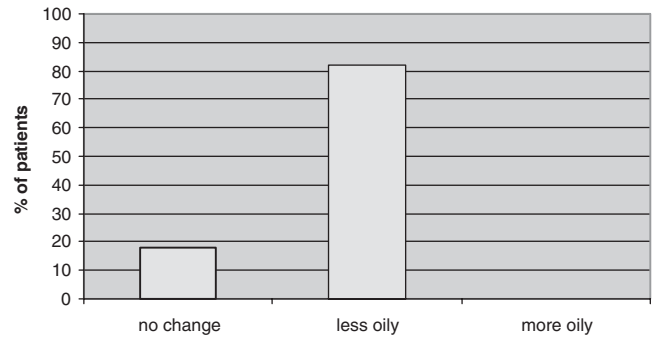


Fig. 5. Patients' subjective response to changes in oiliness after three treatments.

counted on the treated side when compared to the control side. Similarly, we have previously demonstrated that the 1,450-nm diode laser can safely and effectively reduce inflammatory acne lesions on the face [8]. After three treatments, an 83% decrease in mean acne lesion count was noted.

Furthermore, the pulsed-dye laser emits visible light that is absorbed primarily by oxyhemoglobin and decreases post-inflammatory erythema left by acne. *P. acnes* produces endogenous porphyrins that absorb specific wavelengths of visible light and cause lethal oxidative damage to the bacterium thus, reducing colonization of the bacterium and ultimately the number of active inflammatory acne lesions [3,9]. Seaton et al. [9] studied 41 patients with mild-to-moderate inflammatory facial acne. 12 weeks after treatment with the pulsed-dye laser total lesion counts fell by 53% in the treated patients and 9% in the placebo group. Orringer et al. [10] measured the lesion counts of 40 patients in a split-face clinical trial with the pulsed-dye laser. This study showed a trend towards improvement in acne vulgaris when treated with the pulsed-dye laser without being statistically significant.

When used together, the 595-nm pulsed dye laser and the 1,450-nm diode laser may have synergistic effects on acne by targeting different components of the skin. The 1,450-nm diode laser likely shrinks oil glands and decreases oiliness of skin whereas the pulsed dye laser reduces colonization of *P. acnes* and decreases post-inflammatory erythema. All patients experienced improvement, even those with acne recalcitrant to other treatment medications including oral isotretinoin.

In addition to a reduction in active acne lesions, patients reported an improvement of their acne scarring. Dermal heating caused by the 1,450-nm diode laser causes remodeling of dermal collagen [11,12]. Additionally, low fluences of the pulsed dye laser can stimulate procollagen production secondary to non-lethal heating of dermal perivascular tissues that is postulated to alter local cellular metabolism [9]. These mechanisms decrease the appearance of acne scarring. Trelles et al. [13] have shown that combining wavelengths of 595 and 1,450 nm for skin rejuvenation results in overall better and faster results than those obtained with the 595 or 1,450 nm wavelengths alone.

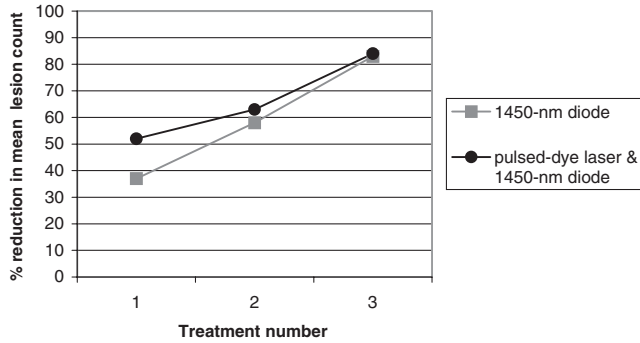


Fig. 6. Comparison of the effects of treatment using the 1,450-nm diode laser alone [8] versus the combination of the pulsed-dye laser and the 1,450-nm diode laser on the percent reduction in mean inflammatory acne lesion counts after one, two, and three treatments. (Data for the percent reduction in mean lesion counts after treatment with the 1,450-nm diode laser alone was taken from an earlier study [8]).

Both the 1,450-nm diode laser alone and the combination of the 1,450-nm diode and the pulsed-dye laser produced a difference in reduction of acne lesion counts after 3 months (Fig. 6) [8]. The combination treatment appears to provide for a faster response time (Fig. 6). After one treatment, a 37% reduction in mean acne lesion count was seen with the use of the 1,450-nm diode laser alone compared to a 52% reduction in mean acne lesion count with the combination of the pulsed-dye laser and the 1,450-nm diode laser. As expected there was also a decrease in post-inflammatory erythema after treatment with the combination of the 595-nm pulsed-dye laser and the 1,450-nm diode laser.

The combination of the 595-nm pulsed-dye laser and the 1,450-nm diode laser appears to be safe for the treatment of inflammatory acne vulgaris. Patients tolerated the treatments well, experiencing mild discomfort. Topical anesthetic use was successful in controlling the pain. Patients reported more discomfort with the 1,450-nm diode laser than with the pulsed-dye laser. In addition, more intense discomfort was felt on the nose and perioral areas as well as on active inflammatory lesions. Side effects were limited to transient erythema and edema that lasted no more than 48 hours after a treatment. No pigmentary changes, purpura, or scarring as a result of the treatment were observed. No long-term adverse effects were recorded.

From our cohort of patients, remission time was seen up to 15 weeks after the last treatment and follow-up is ongoing. Lasers have the potential to produce long-lasting improvements in acne because they cause structural alterations in the sebaceous unit. Paithankar et al. [7] had significant clearance of inflammatory acne for at least

10 weeks after a single treatment and 24 weeks after multiple treatments on the back.

All patients responded favorably to their results and were satisfied with the treatment. Patients reported that they would recommend this treatment to others. We believe the combination of the 595-nm pulsed-dye laser and the 1,450-nm diode laser should be considered as an alternative potentially to isotretinoin or long-term antibiotic therapy, avoiding potentially dangerous and intolerable side effects. Additionally, physicians administer the laser treatment, thus, it is convenient and can be used for patients noncompliant with complicated topical regimens.

We demonstrate that the combination of the 595-nm pulsed dye laser and the 1,450-nm diode lasers is a safe and effective treatment option for patients with inflammatory acne vulgaris, acne scarring, and post inflammatory erythema. Further research into the synergistic effect of combination therapy as well as determination of optimum treatment parameters and the longevity of improvements is warranted at this time.

REFERENCES

1. Stern RS. The prevalence of acne on the basis of physical examination. *J Am Acad Dermatol* 1992;26:931–935.
2. Harper JC. An update on the pathogenesis and management of acne vulgaris. *J Am Acad Dermatol* 2004;51:S36–S38.
3. Shalita AA, Harth Y, Elam M, et al. Acne phototherapy using U.V. free high intensity narrow band blue light-3 center clinical study. *Proc SPIE* 2001;4244:61–73.
4. Cunliffe WJ, Goulden V. Phototherapy and acne vulgaris. *Br J Dermatol* 2000;142:855–856.
5. Papageorgiou P, Katsambas A, Chu A. Phototherapy with blue (415 nm) and red (660 nm) light in the treatment of acne vulgaris. *Br J Dermatol* 2000;142:973–978.
6. Lloyd JR, Mirkov M. Selective photothermolysis of the sebaceous glands for acne treatment. *Lasers Surg Med* 2002;31:115–120.
7. Paithankar DY, Ross EV, Selah BA, Blair MA, Graham BS. Acne treatment with a 1450 nm wavelength laser and cryogen spray cooling. *Lasers Surg Med* 2002;31:106–114.
8. Friedman PM, Jih MH, Kimyai-Asadi A, Goldberg LH. Treatment of inflammatory facial acne vulgaris with the 1450-nm diode laser: A pilot study. *Dermatol Surg* 2004;30:147–151.
9. Seaton ED, Charakida A, Mouser PE, et al. Pulsed-dye laser treatment for inflammatory acne vulgaris: Randomized controlled trial. *Lancet* 2003;362:1347–1352.
10. Orringer JS, Kang S, Hamilton T, et al. Treatment of acne vulgaris with a pulsed dye laser a randomized controlled trial. *JAMA* 2005;291:2834–2839.
11. Friedman PM, Skover GR, Payonk G, Geronemus RG. Quantitative evaluation of nonablative laser technology. *Semin Cutan Med Surg* 2002;21:266–273.
12. Tanzi EL, Alster TS. Comparison of a 1450-nm diode laser and a 1320-nm Nd:YAG in the treatment of atrophic facial scars. A prospective clinical and histologic study. *Dermatol Surg* 2004;30:152–157.
13. Trelles MA, Allones I, Levy JL, Calderhead RG, Moren-Arias GA. Combined nonablative skin rejuvenation with the 595-nm and 1450-nm lasers. *Dermatol Surg* 2004;30:1292–1298.