

## Fractional Photothermolysis for the Treatment of Postinflammatory Erythema Resulting from Acne Vulgaris

ADRIENNE S. GLAICH, MD,\* LEONARD H. GOLDBERG, MD, FRCP,\*<sup>†</sup> ROBIN H. FRIEDMAN, MD,<sup>‡</sup> AND PAUL M. FRIEDMAN, MD\*<sup>§</sup>

*Adrienne S. Glaich, MD, Leonard H. Goldberg, MD, FRCP, Robin H. Friedman, MD, and Paul M. Friedman, MD, have indicated no significant interest with commercial supporters.*

Scarring and postinflammatory erythema are common sequelae of inflammatory acne vulgaris. Treatment modalities based on the theory of selective photothermolysis, including pulsed dye laser, intense pulsed light devices, and potassium titanyl phosphate lasers, may be used to treat vascular conditions.<sup>1-17</sup> Multiple treatment sessions are generally required for satisfactory results.<sup>9,12,13,15,17</sup>

Unlike selective photothermolysis, which produces bulk thermal injury to specific targets in the skin, fractional photothermolysis (Fraxel, Reliant Technologies, Inc., Mountain View, CA) creates hundreds of microthermal treatment zones (MTZs) while sparing the surrounding tissue.<sup>18,19</sup> We report marked improvement of postinflammatory erythema after the resolution of inflammatory acne vulgaris in two patients after one treatment session with fractional photothermolysis.

### Case Report

Two female patients, ages 23 and 36 years, with Fitzpatrick skin types II and IV<sup>20</sup> presented with marked atrophic acne scarring of their cheeks and postinflammatory erythema (present for greater than one year) after resolution of severe active inflammatory acne (Figures 1A and 2A). Clinical experi-

ence has shown that fractional photothermolysis improves acne scarring.<sup>21</sup>

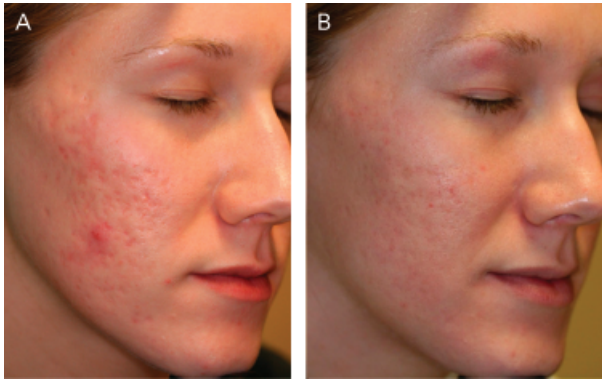
### Preparation for Treatment

The patients' cheeks were cleansed with a mild soap before the procedure. Triple anesthetic cream (10% benzocaine, 6% lidocaine, 4% tetracaine; New England Compounding Center, Framingham, MA) was applied under occlusion to the treatment area for one hour prior to treatment. Once the triple anesthetic cream was removed, an FDA-certified water-soluble tint (OptiGuide Blue) was applied to the treatment area. This allowed the laser's intelligent optical tracking system to detect contact with the skin and to adjust the treatment pattern with respect to handpiece velocity. Lubricating gel (LipoThene, Lipothene, Inc., Pacific Grove, CA) was applied over the OptiGuide Blue to allow the laser handpiece to glide smoothly over the treatment area, and treatment was initiated.

### Treatment Session 1

During the Fraxel treatment session, one patient was treated with a pulse energy of 18 mJ and a density of 125 MTZs/cm<sup>2</sup>. This patient was exposed to 10 laser passes and a total density of 1,250 MTZs/cm<sup>2</sup>. The other patient was exposed to eight laser passes at a

\*DermSurgery Associates, Houston, Texas; <sup>†</sup>Clinical Professor of Dermatology, Department of Dermatology, Weill Medical College of Cornell University, New York, New York; <sup>‡</sup>Memphis Dermatology Clinic, Memphis, Tennessee; <sup>§</sup>Department of Dermatology, University of Texas Medical School, Houston, Texas



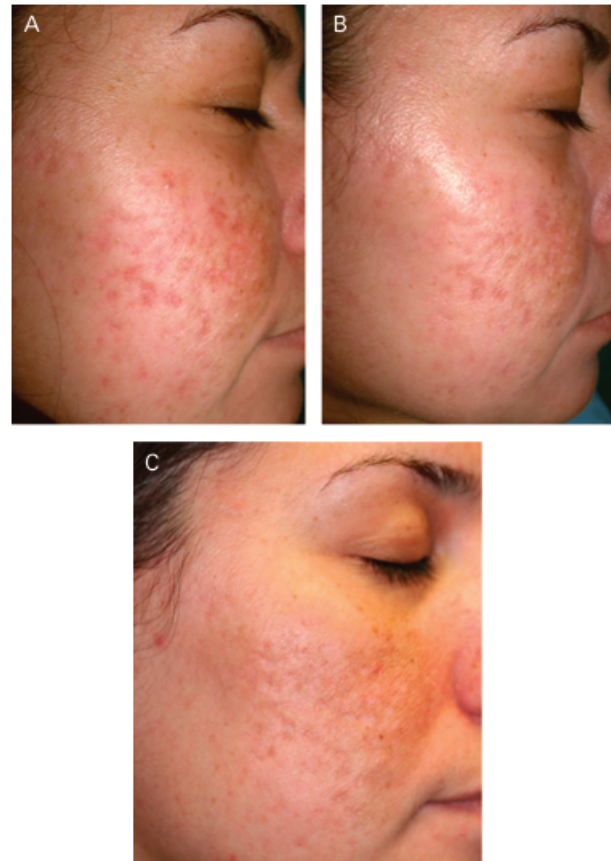**Figure 1.** (A) Right cheek before Fraxel laser treatment. Note the postinflammatory erythema at the sites of the atrophic and ice-pick acne scars. (B) Marked improvement in the postinflammatory erythema and acne scarring 3 months after five Fraxel laser treatments.

density of 250 MTZs/cm<sup>2</sup>, corresponding to a total density of 2,000 MTZs/cm<sup>2</sup>. The pulse energy applied was 6 mJ. During the Fraxel laser treatment, a skin cooling device (Zimmer Elektromedizin Cryo 5, Zimmer MedizinSystems, Irvine, CA) was used to cool the skin and mitigate patient discomfort (fan power 2; 4–6 in. from the skin surface).<sup>22</sup> Side effects of the treatment were limited to mild posttreatment erythema and edema, which resolved in 24 to 48 hours.

Treatment parameters were selected to deliver high-pulse energies to maximize penetration depth for optimum results and adjusted based on each patient's pain threshold. The density was decreased as the pulse energy increased to minimize excessive heat delivered to small areas. A lower pulse energy was selected for the patient with Fitzpatrick skin type IV to reduce the risk of postinflammatory hyperpigmentation. The energies were slowly increased with subsequent treatments.

### **Results after Treatment 1**

Photographic documentation and clinical improvement scores were determined preprocedure and at 2 weeks after the Fraxel treatment. Follow-up results after a single treatment revealed a marked clinical improvement in the degree of postinflammatory erythema based on independent physician clinical assessments using a quartile grading scale



**Figure 2.** (A) Right cheek before Fraxel laser treatment. (B) One month after a single Fraxel laser treatment (6 mJ, 2,000 MTZs/cm<sup>2</sup>). Note the marked reduction in the postinflammatory erythema compared to baseline (A). (C) Right cheek after six Fraxel treatments demonstrating marked improvement in acne scarring from baseline.

(0%–25% = minimal to no improvement; 25%–50% = mild improvement; 51%–75% = moderate improvement; >75% = marked improvement.) Incidentally, physician clinical assessments also revealed mild improvement from baseline in atrophic acne scarring after a single Fraxel treatment. The patient's degree of satisfaction paralleled the physician's assessment of improvement (Figure 2B).

### **Additional Treatment Sessions**

Both patients returned for additional Fraxel laser treatments for the treatment of atrophic acne scarring. One patient had five Fraxel laser treatments at 4-week intervals with pulse energies ranging from 20 to 24 mJ and total densities of 1,000 to 1,250 MTZs/cm<sup>2</sup> (Table 1).

**TABLE 1. Fraxel Laser Treatment Parameters**

Treatment No.	Patient 1 (23 years; FST II)		Patient 2 (36 years; FST IV)	
	Energy (mJ)	Total density (MTZ/cm <sup>2</sup> )	Energy (mJ)	Total density (MTZ/cm <sup>2</sup> )
1	18	1,250	6	2,000
2	20	1,125	6	2,000
3	22	1,125	6	2,000
4	22	1,000	7	2,000
5	24	1,250	7	2,000
6	N/A	N/A	8	2,500

FST, Fitzpatrick skin type; MTZ, microthermal zone.

The other patient had six Fraxel laser treatments at 2- to 4-week intervals with energies ranging from 6 to 8 mJ and total densities of 2,000 to 2,500 MTZs/cm<sup>2</sup> (Table 1). Concomitant use of the Zimmer Elektro-medizin Cryo 5 during Fraxel treatment was used to cool the skin and mitigate patient discomfort (fan power 2; 4–6 in. from the skin surface).<sup>22</sup>

### Results after the Last Treatment

Using a quartile scale, physician clinical assessments revealed moderate to marked clinical improvement in atrophic acne scarring of both patients 3 months after the last Fraxel treatment (Figures 1B and 2C). Continued improvements in erythema were also noted after additional treatments. Both patients demonstrated persistence of improvement 3 months after their last treatment.

### Discussion

These cases illustrate the effectiveness of a single treatment of fractional photothermolysis for postinflammatory erythema resulting from acne vulgaris. After additional treatments, continued improvement in the erythema as well as improvement in the acne scarring was noted. The 1,550-nm wavelength utilized in fractional photothermolysis targets tissue water, a major element of blood vessels. Irradiation at 1,550 nm may lead to photothermal microvascular destruction of dermal vasculature resulting in improved erythema. Furthermore, the laser produces

hundreds to thousands of microthermal zones of injury in the dermis that may result in frequent, random hits to the dermal blood vessels. This theory is supported by recent reports demonstrating histologic evidence of damage to dermal vasculature in patients undergoing fractional photothermolysis.<sup>11,23</sup> Blood vessels located at various skin depths can be targeted for treatment by adjusting the optical focal depth (determined by the pulse energy) of fractional photothermolysis.<sup>18</sup> Additionally, the operator can adjust the MTZ density to achieve optimal clinical results. A recent clinical study indicated effectiveness of fractional photothermolysis for poikiloderma of Civatte.<sup>11</sup> No reports of this modality for the treatment of postinflammatory erythema have been described, however.

Unlike conventional lasers that use a single-beam laser, fractional photothermolysis employs a microbeam-composed laser that minimizes the risk of bulk heating to the dermis. With a density of 1,000 MTZs/cm<sup>2</sup> at 20 mJ, for instance, only about 20% of the treated area is actually heated, reducing the risk of irreversible, thermal injury to the dermis, which may worsen the erythema. Fractional resurfacing is achieved with a limited amount of injury to the treatment zone(s) and short migratory paths for keratinocytes leading to fast epidermal repair.<sup>19</sup> Little water is contained in the stratum corneum so it remains functionally unimpaired after treatment with fractional photothermolysis. This significantly reduces the risk of infection or other untoward side effects.

The pulsed dye laser is commonly used for the treatment of dermal blood vessels. Utilizing the principle of selective photothermolysis, this laser destroys the vascular component in the dermis leading to clinical improvement.<sup>24,25</sup> Complete clearing of postinflammatory erythema after the resolution of acne scarring is slow and may not always be achieved. Furthermore, multiple treatment sessions are usually required for optimal clearing. One possible explanation for the limited therapeutic outcome is the limited light penetration depth in blood at the 585- to 595-nm wavelength, which is about 52  $\mu\text{m}$ .<sup>26</sup> The 1,550-nm wavelength used in fractional photothermolysis allows penetration of approximately 1,000  $\mu\text{m}$  into the skin,<sup>27</sup> which makes fractional photothermolysis of more deeply located blood vessels possible and a benefit compared to the pulsed dye laser which cannot penetrate to this depth.

In these patients marked clinical improvement in erythema was obtained after a single fractional resurfacing treatment. Both patients demonstrated persistence of improvement 3 months after their last treatment. These case reports demonstrate that fractional photothermolysis is a safe and promising new treatment modality for postinflammatory erythema resulting from acne vulgaris. The rapid improvement of the telangiectatic component of postinflammatory erythema with fractional photothermolysis further underscores the potential benefit of this device for vascular lesions. Additional controlled, split-face studies with more patients and longer-term follow-up are necessary to further evaluate the efficacy and safety of fractional photothermolysis for treatment of postinflammatory erythema and to define optimal treatment parameters.

## References

- Anderson RR, Parrish JA. Selective photothermolysis: precise microsurgery by selective absorption of pulsed dye laser. *Science* 1983;220:524-7.
- Woo SH, Ahn HH, Kim SN, Kye YC. Treatment of vascular skin lesions with the variable-pulse 595 nm pulsed dye laser. *Dermatol Surg* 2006;32:41-8.
- Astner S, Anderson RR. Treating vascular lesions. *Dermatol Ther* 2005;18:67-81.
- Schmults CD. Laser treatment of vascular lesions. *Dermatol Clin* 2005;23:745-55.
- Alster TS, McMeekin TO. Improvement of facial acne scars by the 585 nm flashlamp-pumped pulsed dye laser. *J Am Acad Dermatol* 1996;35:79-81.
- Smit JM, Bauland CG, Wijnberg DS, Spauwen PH. Pulsed dye laser treatment, a review of indications and outcome based on published trials. *Br J Plast Surg* 2005;58:981-7.
- Clark C, Cameron H, Moseley H, et al. Treatment of superficial cutaneous vascular lesions: experience with the KTP 532 nm laser. *Lasers Med Sci* 2004;19:1-5.
- Schroeter CA, Haaf-von Below S, Neumann HA. Effective treatment of rosacea using intense pulsed light systems. *Dermatol Surg* 2005;31:1285-9.
- Tan ST, Bialostocki A, Armstrong JR. Pulsed dye laser therapy for rosacea. *Br J Plast Surg* 2004;57:303-10.
- Iyer S, Fitzpatrick RE. Long-pulsed dye laser treatment for facial telangiectasias and erythema: evaluation of a single purpuric pass versus multiple subpurpuric passes. *Dermatol Surg* 2005;31:898-903.
- Behroozan DS, Goldberg LH, Glaich AS, et al. Fractional photothermolysis for treatment of poikiloderma of Civatte. *Dermatol Surg* 2006;32:298-301.
- Batta K, Hinson C, Cotterill JA, Foulds IS. Treatment of poikiloderma of Civatte with potassium titanyl phosphate (KTP) laser. *Br J Dermatol* 1999;140:1191-2.
- Geronemus RG, Kauvar AN. Successful treatment of poikiloderma of Civatte utilizing the pulsed dye laser. *Lasers Surg Med* 1999;11(S11):62.
- Weiss RA, Goldman MP, Weiss MA. Treatment of poikiloderma of Civatte with an intense pulsed light source. *Dermatol Surg* 2000;26:823-7.
- Geronemus R. Poikiloderma of Civatte. *Arch Dermatol* 1990;126:547-8.
- Glaich AS, Friedman PM, Jih MH, Goldberg LH. Treatment of inflammatory facial acne vulgaris with combination 595-nm pulsed-dye laser with dynamic-cooling-device and 1,450-nm diode laser. *Lasers Surg Med* 2005;38:177-80.
- Alam M, Pon K, Van Laborde S, et al. Clinical effect of a single pulsed dye laser treatment of fresh surgical scars: randomized controlled trial. *Dermatol Surg* 2006;32:21-5.
- Manstein D, Herron GS, Sink RK, et al. Fractional photothermolysis: a new concept for cutaneous remodeling using microscopic patterns of thermal injury. *Laser Surg Med* 2004;34:426-38.
- Khan MH, Sink RK, Manstein D, et al. Intradermally focused laser pulses: thermal effects at defined tissue depths. *Laser Surg Med* 2005;36:270-80.
- Fitzpatrick TB. The validity and practicality of sun-reactive skin types I through VI. *Arch Dermatol* 1988;124:869-71.
- Alster TS, Tanzi EL, Lazarus M. The use of fractional photothermolysis for the treatment of atrophic scars. *Dermatol Surg* 2007;33:295-9.

22. Fisher GH, Kim KH, Bernstein LJ, Geronemus RG. Concurrent use of a handheld forced cold air device minimizes patient discomfort during fractional photothermolysis. *Dermatol Surg* 2005;31:1242-4.
23. Laubach HJ, Tannous Z, Anderson RR, Manstein D. A histological evaluation of the dermal effects after fractional photothermolysis treatment. *Laser Surg Med* 2005;36(S17): 86.
24. Alster T. Improvement of erythematous and hypertrophic scars by the 585-nm flashlamp-pumped pulsed dye laser. *Ann Plast Surg* 1994;32:186-90.
25. Alster TS. Laser treatment of hypertrophic scars, keloids and striae. *Dermatol Clin* 1997;15:419-29.
26. Van Gemert MJ, Welch AJ, Pickering JW, Tan OT. Laser treatment of port wine stains. In: Welch AJ, Van Gemert MJ, editors. *Optical-thermal response of laser-irradiated tissue*. New York: Plenum Press; 1995:p. 789-830.
27. Irvine WM, Pollack JB. Infrared optical properties of water and ice spheres. *Icarus* 1968;8:324-60.

---

Address correspondence and reprint requests to:  
Paul M. Friedman, MD, DermSurgery Associates, 7515  
Main Street, Suite 210, Houston, TX 77030, or  
e-mail: pmfriedman@dermsurgery.org